

**PATIENT**

Tinker Cornelius

**SPECIES**

Feline

**BREED**

DLH

**SEX**

Female Spayed

**AGE**

10.10 years

**WEIGHT**

15lbs

**INTERPRETED BY**

Maggie Machen Lamy,  
DVM, DACVIM  
(Cardiology)

**IMAGING PERFORMED BY**

Loetitia Saint-Jacques,  
LVT

**HOSPITAL NAME**

VCA Feline Animal  
Hospital

**REFERRING VET**

NP

**INVOICE**

46823

**DATE**

2/12/26

**PRESENTING CLINICAL SIGNS**

History: History of GI upset. No current medications, supplements, or preventatives. No arrhythmia/No murmur. Labs: WNL. Owner requested echo.

**ELECTROCARDIOGRAPHIC FINDINGS**

A six lead ECG is available at 25mm/s; 20mm/mV. The average heart rate is 230bpm. Low voltage complexes and artifact impede detailed interpretation. The rhythm is sinus in origin, with a p for every QRS complex and vice versa. The P wave morphology is positive with a normal dimension. Normal PR. The QRS morphology is positive with normal dimension. MEA is normal. No ectopic beats, pauses or dysrhythmias observed. ECG diagnosis: Normal sinus tachycardia.

**ECHOCARDIOGRAM FINDINGS**

2D, m-mode, color flow and doppler imaging is available. The left ventricular wall is normal in dimension. There is a mildly hyperechoic endocardium consistent with mild fibrosis. The endocardium also appears mildly remodeled. The papillary muscles are normal in size and hyperechoic. The left atrium is normal in size. The right atrium is normal in size. The right ventricle appears normal. The mitral valve is normal in structure and mobility. No obvious valve regurgitation. Blood flow through both the LVOT and RVOT is normal in velocity. No pleural or pericardial effusion seen. No obvious cardiac tumors.

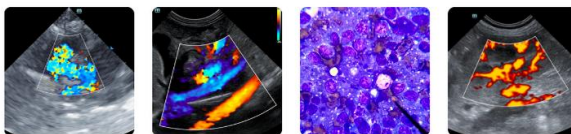
**CARDIAC CHART**

| FELINE CARDIAC PARAMETERS | BODY WEIGHT (kg)               | HR (BPM)  | IVSd (cm)<br><small>(Moise, Pipers)</small>                | LVIDd (cm)<br><small>(Moise, Pipers)</small> | LVWd (cm)<br><small>(Moise, Pipers)</small> | FS (%)                        | EF (%) |
|---------------------------|--------------------------------|---|--|--|---|-------------------------------|--------|
| <b>NORMAL PARAMETER</b>   | -----                          | 150-240   | 0.35-0.55  | <2<br>(mean 1.5)                             | 3.5-0.55                                    | 35-67                         | 80-100 |
| <b>PATIENT</b>            | 6.8                            | NM  | 0.50   | 1.4  | 0.49  | 52                            | 86     |
| FELINE CARDIAC PARAMETERS | LA/AO<br><small>(Boon)</small> | LA/AO HEART BASE (Swe)<br><small>(Abbott)</small> | LA 2D short axis Base view (cm)<br><small>(Abbott)</small> | LVOT VEL<br><small>(m/s)</small>             | RVOT VEL<br><small>(m/s)</small>            | E max<br><small>(m/s)</small> |        |
| <b>NORMAL</b>             | <1.5                           | <1.3  | <1.2   | <1.6   | <1.3  | <0.9                          |        |
| <b>PATIENT</b>            | NM                             | 1.2   | 1.1  | 0.9  | 1.1   | NM                            |        |

*\*Note: All measurements based upon multi-modal images and methods. An average value is reported.*  
Adapted from June Boon, Veterinary Echocardiography, 1998  
Abbott J & MacLean H JVIM 2006;20: 111-119, Moise et al. Am J Vet Res 47:1476, 1986. Pipers et al. Am J Vet Res 40:882, 1979.

**INTERPRETATION OF THE FINDINGS & FURTHER RECOMMENDATIONS**

Overtly normal cardiac structure and function. The LV wall thickness is normal, and there is no evidence of elevated left atrial pressure or underlying pathology at this time. There is mild remodeling and fibrosis of the left ventricular wall, which is considered likely a normal age-



**PATIENT**

Tinker Cornelius

**SPECIES**

Feline

**BREED**

DLH

**SEX**

Female Spayed

**AGE**

10.10 years

**WEIGHT**

15lbs

**INTERPRETED BY**

Maggie Machen Lamy,  
DVM, DACVIM  
(Cardiology)

**IMAGING PERFORMED BY**

Loetitia Saint-Jacques,  
LVT

**HOSPITAL NAME**

VCA Feline Animal  
Hospital

**REFERRING VET**

NP

**INVOICE**

46823

**DATE**

2/12/26

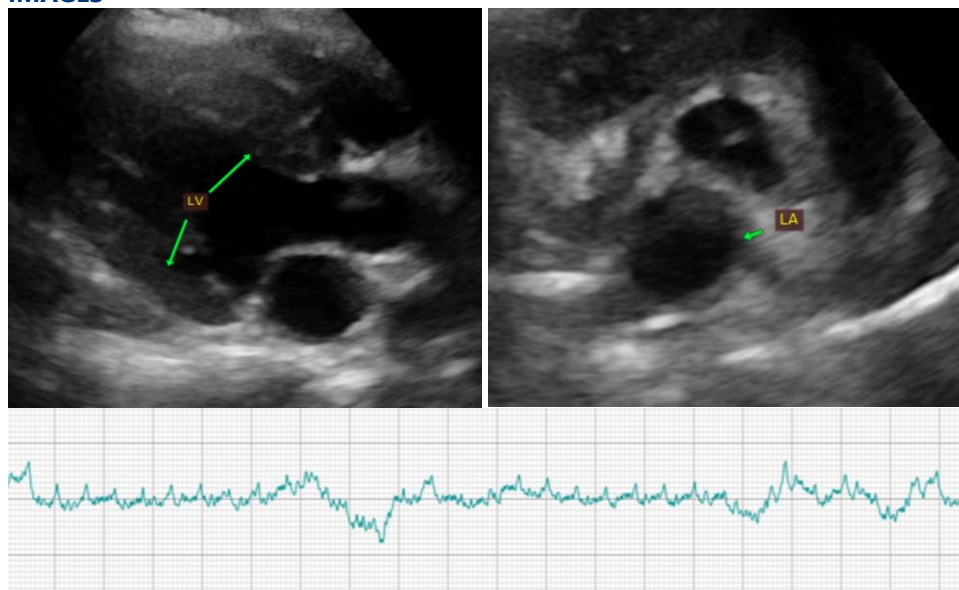
related finding. Flow through the great vessels is normal, and no significant valve regurgitation is identified. The ECG is unremarkable with a normal sinus tachycardia.

Given these findings, no medications are indicated. Prognosis is good.

Anesthetic risk is considered mild. Risk for complication with steroid use or fluid administration typically follows LA dilation, which in this case is low. That being said, any cat can experience unexpected signs of intolerance and monitoring of RR/RE is advised particularly in the initiation phase.

Recommend recheck echocardiogram in 1 year to assess for any progressive issues.

**IMAGES**



**The information and recommendations provided are based on the images presented by the referring veterinarian. No evaluation can be communicated regarding pathology that was not visible in the image/video clips provided.**

Thank you for this referral. This report was generated using transcription software, and minor dictation errors may be present. If the clinical or image interpretation does not parallel your findings or if I can be of any further assistance, please contact me.

**Maggie Machen Lamy, DVM**  
**Diplomate of the American College of Veterinary Internal Medicine (Cardiology)**  
info@sonopath.com